Egyptian
Orthodontic Journal

THE EFFECTS OF COMBINED SKELETAL ANCHOR PLATES AND REMOVABLE TMA TRACTION SPRINGS IN GROWING PATIENTS WITH MAXILLARY DEFICIENCY

Eid H. S.[1], Elsayed W[2].

ABSTRACT:

The purpose of this study was to evaluate the efficiency of bone anchored maxillary protraction (BAMP), using combined skeletal maxillary mini plates and a removable TMA traction spring appliance (TTSA), in patients with Class III malocclusion. Twenty cases (n=20) who were in prepubertal skeletal growth periods were used in the study. All subjects had skeletal and dental Class III malocclusions with maxillary deficiency, and anterior crossbite. The samples were categorized into two groups: Group A comprised 6 girls and 4 boys (n=10) (mean age, 11.91 years) received treatment using (BAMP). Three hundred fifty to 400 g of force per side was applied to the (TTSA) from the titanium miniplates (HUBIT, Korea) inserted in each infrazygomatic buttress of the maxilla. Total treatment time was 6.9±2.63 months. Group B comprised 7 girls and 3 boys (n=10) (mean age, 11.05 years) was the untreated control group. Lateral cephalometric films were obtained at the beginning (T1), at the end of treatment (T2) and at follow up 6 months later in both groups and analyzed with independent-sample t tests (P <0.05).The miniplates were able to withstand the orthopedic forces exerted during active treatment. Cephalometric findings showed significant sagittal measurements of the maxilla, as well as significant improvements in the

1- Lecturer of Orthodontics, Faculty of Dentistry, Misr University for Science and Technology.
2- Lecturer of Orthodontics, Faculty of Dentistry, Suez Canal University.

mandibular skeletal measures at Point B, where SNA and SNB angles have improved significantly between T1 and T2 (p <0.001) without significant maxillary incisor movement. Statistically significant increases were observed in the vertical dimension, where rotation of the mandible and increased facial height were evident.

Compared with growth of the untreated Class III subjects, it is suggested that this treatment approach can offer an advantage for correcting Class III patients with mild/moderate maxillary deficiency.

INTRODUCTION

When growing individuals are encountered with Class III malocclusion, a deviation in the sagittal relationship of the maxilla and the mandible is often found, in the form of maxillary deficiency and/or mandibular prognathism.[1]Early treatment of Class III malocclusion has been advocated to reduce the need of treatment in the permanent dentition, when camouflage orthodontic treatment or surgery becomes the only options.[2]A series of treatment approaches can be found in the literature regarding orthopedic treatment in Class III malocclusion. Protraction face-mask therapy or reverse-pull headgear (RPHG) is perhaps the most common approach for early treatment of Class III patients with maxillary deficiency. This approach is limited in that the forces are applied to the teeth, resulting in uncertain skeletal and often unwanted dentoalveolar effects.[3,4] Several appliance modifications have been encountered to minimize tooth movement and maximize orthopedic correction. However, some dento alveolar effects are difficult to avoid, simply because the necessity to use teeth as anchorage results in stimulation of the periodontal membrane and dissipation of the protraction force transmitted to the circummaxillary sutures. Previous studies has shown the treatment results are often in the form of combined dental movements and orthopedic displacement of the maxilla.[3-9] This results in proclination of the maxillary incisors,[3,5,7,9] retroclination of the mandibular incisors, as well as extrusion of the maxillary first permanent molars.[3,9] It is worthy to

note that the above treatment outcomes are usually difficult to achieve unless the patient is fully compliant with wearing the extraoral appliance, where the required treatment regimens recommend for wearing the appliance were 12 to 16 hours per day for 9 to 12 months.[3,4]

Many studies have offered a solution to the above unwanted treatment results, among them; the application of force to purposefully ankylosed deciduous canines for direct transmission of force to the circummaxillary sutures.[10,11] However, the anchor teeth inevitably resorb as their permanent successors erupt.[12,13]Osseointegrated implants are an alternative method of obtaining attachment of a traction force directly to the maxilla in the form of bone anchored maxillary protraction (BAMP). Implants have been demonstrated to be biologically compatible[14,15] and to provide absolute anchorage when subjected to orthodontic forces in both animal models[16-18] and in human case reports.[19-22] Implants have also been shown to provide absolute anchorage when subjected to orthopedic force in animal models.[23-25]More recent reports from Singer et al,[26] Enacar et al,[27] Hong et al,[28]Kircelli and Pektas,[29] and Kircelli et al[30] demonstrated the potential for (BAMP) as adjuncts to orthopedic maxillary protraction.

This study was carried out to introduce a combination of (BAMP) and a lower arch removable intraoral TMA traction spring appliance (TTSA),[31] for the treatment of growing Class III individuals. Inetrmaxillary traction resulted from such combination can be more esthetic, and more comfortable than the conventional devices as no parts are showing extraorally. Being a removable appliance, facilitates good oral hygiene, and allowing treatment to be suspended or restarted whenever necessary. The unique metallurgy of the T.M.A. 0.036 inch wire with patented beta-phase alloy of molybdenum, offered half the force and twice the working range of stainless steel.[32] In addition to its high resiliency and adequate formability, made it an excellent replacement for intermaxillary elastics used along with (BAMP) and mandibular more anteriorly positioned implants,[32,33]where this treatment protocol is prone to suffer an inadequately controlled and unstable force delivery, as well as their susceptibility to deterioration in intraoral enviroment.[34]

MATERIALS AND METHODS

Twenty cases (n=20) who were in prepubertal skeletal growth periods were used in the study. Criteria for participation in the study were 9–14 years of age at the start of treatment, skeletal Class III due primarily to maxillary deficiency (determined by cephalometric and clinical examination including profile evaluation), Class III dental occlusion determined by the permanent first molars position or overjet≤0 m. All patients were at prepubertal cervical vertebra maturation stages. The samples were categorized into two groups: Group A comprised 6 girls and 4 boys (n=10) (mean age, 11.91 years) received treatment using (BAMP). Group B comprised 7 girls and 3 boys (n=10) (mean age, 11.05 years) was the untreated control group that matched the treated group regarding type of dentoskeletal disharmony and skeletal maturation.

In the surgical procedure, 2 miniplates were placed in each patient (HUBIT, Korea) (Fig1), 1 in each infrazygomatic buttress of the maxilla. Flaps were reflected in these sites, and the devices were secured by using titanium miniscrews after pilot hole preparation (Fig 2).[35]In all sites, the miniplates were placed with the attachment hook exiting through attached tissue at or near the mucogingival junction (Fig 3). All mucoperiosteal flaps were secured with 4/0 resorbable sutures. All surgical procedures for all patients were done by the same experienced oral surgeons. The surgical sites were allowed to heal for 2 to 3 weeks before orthopedic loading. The surgical procedures were well tolerated by patients.[36]

Fig. 1: Titanium miniplates for (BAMP) (HUBIT, Korea)

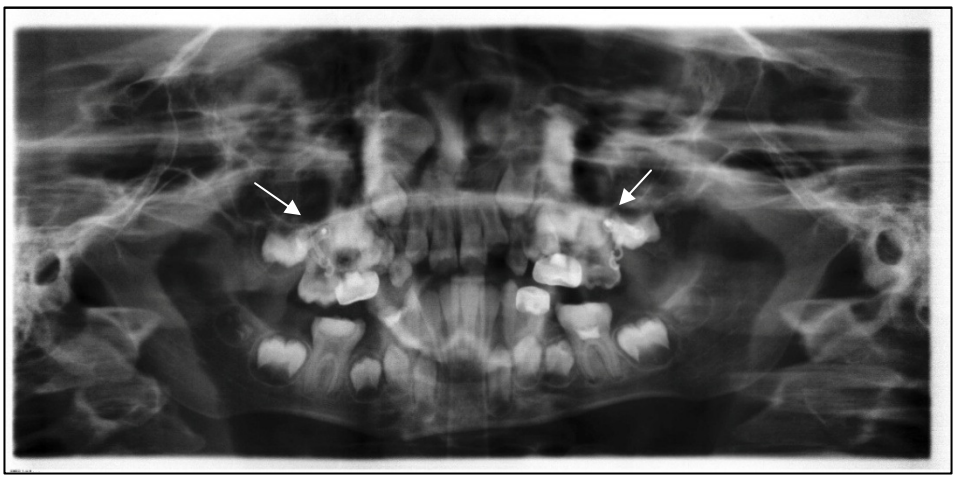

Fig. 2: Panoramic x-ray showing 2 miniplates (arrows)(HUBIT, Korea) placed 1 in each infrazygomatic buttress of the maxilla (case 1)

Fig. 3: Attachment hook exiting through attached tissue at or near the mucogingival junction (Case 1)

The TMA Traction Spring Appliance (TTSA) comprised of a TMA spring, embedded in a lower removable acrylic splint one on each side. The splint covered the lingual and occlusal surfaces of lower teeth, and rendered removable by means of previously fabricated retention clasps (Fig 4). The TMA springs were made from 0.036" straight form TMA wire (Ormco- Sybron- U.S.A.) shaped into vertical spring loops adapted to fit in the lower buccal sulcus on each side (Fig 5).The springs were embedded from one end in the lower acrylic removable splint, and connected in the activated state to theattachment hooks of the miniplates secured to the maxilla. The miniplates were loaded 3 weeks after surgery giving vectors of force downward and forward for the maxilla. Three hundred fifty to 400 g of force per side were applied to the titanium miniplates from the (TTSA). The forces were measured with the patient in centric relation by using a Correx force gauge (Haag-Streit, Bern, Switzerland). The patients were instructed to wear the (TTSA) 12-14 hours per day at evening and night time. Oral hygiene instructions were given with particular emphasis on brushing the tissues around the miniplates with a soft toothbrush.

Fig. 4: Removable TTSA



Fig. 5: TMA springs (0.036")
(Ormco- Sybron- U.S.A.)

The decision to discontinue orthopedic treatment was made when the clinician judged that adequate positive overjet was achieved. To visualize the treatment changes, lateral cephalometric x-rays were taken immediately after placement of the miniplates (T1), at approximately 8 months (T2) or the conclusion of the orthopedic treatment whichever came first, and after post-treatment at 6 months (T3). Same measurements were taken for control group at same time intervals. Parameters were measured to the nearest degree from lateral cephalograms. The radiographs were traced on 0.07-mm acetate paper in a semidark room (Fig 6).

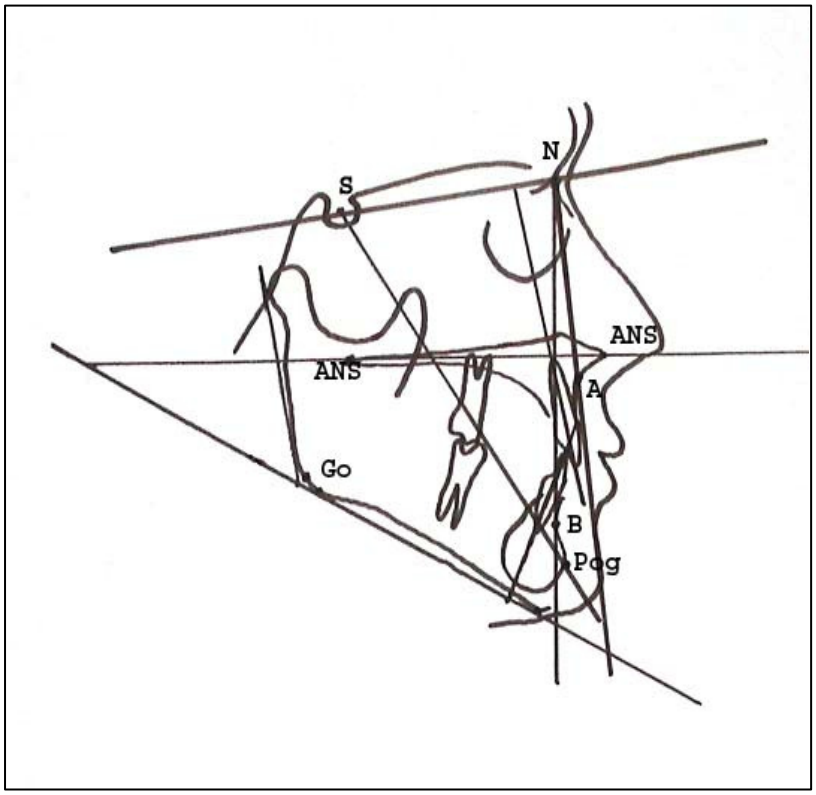

Fig. 6: Cephalometric landmarks and measurements used in the study

STATISTICAL METHODS

Statistics were done by computer using epi- info. software, version 6.04. a word processing, database and statistics program (WHo, 2001). The tests used were:

Mean, and standard deviation: to measure the central tendency of data and the distribution of data around their mean value.

Student's T-test: for testing statistical significant difference between mean values of two samples.

Paired T-test Pt: to test for significant difference between two readings for the same person.

RESULTS

The anterior cross bite was corrected in each patient of appliance therapy group, leading to an improvement of soft tissue Profile as well as the relationship between the upper and lower lip. Lateral cephalograms were taken at the beginning of treatment, at the end of orthopedic treatment, and at follow-up 6 months later months later for group A. Same measurements were taken for control group at same time intervals (tables 1&2). Cephalometric evaluation between the beginning of treatment and end of treatment showed a significant increase of SNA, ANB, and Wits values in all treatment group cases. Clockwise rotation of the mandible was also observed leading to a decrease in SNB, meanwhile, no rotation was observed in the maxilla. No major changes occurred in the upper incisor inclination, whereas the lower incisors were retroclined. During the follow-up period (from end of treatment to 6 months later), the Class III correction was maintained (table 2). Overall, the changes between T1 and T2 showed significant active treatment effects leading to major improvements in the treated group vs. the control group that did not show any significant improvements (Fig 7).

Table I: Descriptive statistics for all patients, showing cephalometric measurements at T1 (dg):

Parameter	N	Mean	S.D	Minimum	Maximum
SNA	20	78.3250	4.3476	76.0000	82.0000
SNB	20	83.6750	4.8809	78.0000	83.0000
ANB	20	-5.3500	4.0940	-2.0000	-6.5000
MP-SN	20	34.7250	6.0251	22.0000	38.0000
PP-SN	20	8.4500	3.2237	2.0000	13.0000
Wits	20	-3.1233	3.6631	-2.0000	-4.0000
U1-SN	20	108.8250	4.3167	96.0000	115.0000
L1-MP	20	83.0000	8.1435	77.0000	94.0000

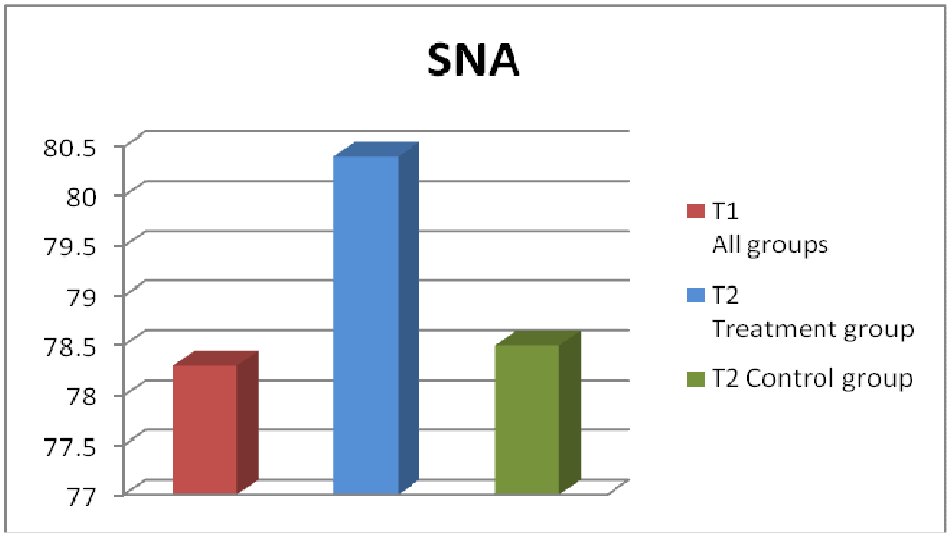

Figure 7: Bar graph showingmean changes of treatment group compared to control group regarding SNA (dg).

Table II. Paired t test showingskeletal changes, due to appliance therapy (dg).

Parameter	No. of pts.	Mean value				Mean difference	Standard Deviation difference	Paired "t" test	P value
SNA	10	T1	78.32	T2	80.47	2.1538	1.197	4.31	<0.001***
	10	T2	80.47	T3	79.61	0.8604	0.8861	0.57	>0.05*
	10	T1	78.32	T3	79.61	1.2904	1.2558	3.70	<0.01***
SNB	10	T1	83.67	T2	82.15	-1.525	1.3156	-5.18	<0.001***
	10	T2	82.15	T3	82.84	0.6962	1.03	2.44	>0.05*
	10	T1	83.67	T3	82.84	-0.8288	0.9268	-3.22	<0.001***
ANB	10	T1	-5.35	T2	-1.68	3.6755	3.7813	2.04	<0.001***
	10	T2	-1.68	T3	-3.23	-1.5501	1.1929	-2.11	>0.05*
	10	T1	-5.35	T3	-3.23	2.1233	3.6171	1.02	<0.01***
MP-SN	10	T1	34.72	T2	37.22	2.5	1.9944	5.61	<0.001***
	10	T2	37.22	T3	36.73	-0.49	1.5862	-1.12	>0.05*
	10	T1	34.72	T3	36.73	2.01	1.7858	5.06	<0.001***
PP-SN	10	T1	8.45	T2	8.57	0.125	1.05	0.53	>0.05*
	10	T2	8.57	T3	9.30	0.732	1.3481	1.96	>0.05*
	10	T1	8.45	T3	9.30	0.8577	1.5761	1.96	>0.05*
Wits	10	T1	-3.12	T2	-0.87	2.255	1	11.4	<0.001***
	10	T2	-0.87	T3	0.66	-0.210	1.08	-0.72	>0.05*
	10	T1	-3.12	T3	0,66	2.332	1.35	6.21	<0.001***
U1-SN	10	T1	108.8	T2	113.8	5.00	3.9023	5.73	<0.001***
	10	T2	113.8	T3	112.7	-1.1327	3.6206	-1.13	>0.05*
	10	T1	108.8	T3	112.7	3.8673	2.595	5.37	<0.001***
L1-MP	10	T1	83.00	T2	79.05	-3.95	3.6308	-4.87	<0.001***
	10	T2	79.05	T3	80.38	0.8846	2.2094	1.44	>0.05*
	10	T1	83.00	T3	80.38	-2.6154	2.5695	-3.67	<0.001***

p >0.05*: non significant - p <0.05**:significant - p (<0.01*** or <0.001***):highly significant

DISCUSSION

The purpose of this study was to evaluate a new treatment approach for growing Class III patients regarding skeletal and dental changes. The main reason behind using bone anchored maxillary protraction was that this treatment would result in orthopedic correction without adverse dent alveolar effects. The use of skeletal anchorage in the maxilla for orthopedic Class III treatment has been reported previously but always combined with facemask therapy.[26-29]The lack of a need for extraoral appliances in this study might have favorably affected compliance to wear the appliance. In other words, this appliance can be tolerated or accepted in some better way than other available rather bulky and esthetically compromised appliances used to treat similar conditions. Few complaints regarding mild vestibular irritation has occurred, but was relieved by adjusting the buccolingual position of the spring helix.

Other studies reported the use of maxillary protraction with intermaxillary elastics to miniplates secured in maxilla and mandible.[37,38] Though this seems the perfect solution to compliance, but the control of force levels sourced from intraoral elastics is difficult due to the inherent elastic properties of elastomers,[34] as treatment took longer times to achieve satisfactory results compared to the present study, whereas one time activation was satisfactory for 3 weeks period of force stability.

Every patient used the appliance as instructed gained anterior crossbite improvement and eventually improvement in his or her facial profile depending on the severity of the case (figures 8-10) as evidenced by the significant increase of SNA, ANB, and Wits values in all treatment group cases (Table 2). Cases were resolved regarding class III malocclusion in average 8 months period, providing that they were mild to moderate in severity (table 1). However severe cases even though improved, they were excluded from the study and received alternative treatment plan according to degree of severity.

The present study showed significant decrease in SNB, this decrease can be explained by the significant increase in the vertical skeletal

measurements represented by; MP-SN angle (table 2). Eventually, backward and downward rotation of the mandible reflected the SNB improvement; these results matched the finding of previous studies in the literature.[39-41] When Bjork[42] in 1969, divided patients with classified malocclusions into forward and backward rotators, he pointed out that forward rotators are easier to treat. On the other hand, patients with high MP-SN angles and gonial angles, along with other criteria described by Skieller et al.[43] in 1984, (inclination of premolars and molars being more inclined than in forward rotators, convex or notched lower border of the mandible and decreased ramus height measurements), would be classified as backward rotators. Now it is clear that such patients cannot use the appliance with the present prescription of amount of force or time used, as it would be difficult to prevent opening of the bite and further increase in the height of the lower anterior face. Therefore, it is recommended that some modifications must be encountered in design and use of the appliance.

Previous investigations evaluated skeletal changes produced by either rapid maxillary expansion and face mask therapy[44] or maxillary protraction in association with a chincup[45]. Where the maxillary expansion and protraction study showed less pronounced maxillary changes when compared with the effects of the treatment protocol used in this study.

No significant forward movement of the upper central incisorswas noticed in this study (table 2), this positive effect when compared to the study by Chang et al.[45] which revealed marked dentoalveolar contributions to the general effect of therapy. Thus the use of the bone anchors in the BAMP protocol allowed for a decent amount of skeletal change without or less dentoalveolar movements.

CONCLUSIONS

Compared with growth of the untreated Class III subjects, it is suggested that this treatment approach can offer an advantage for correcting Class III patients with mild/moderate maxillary deficiency.

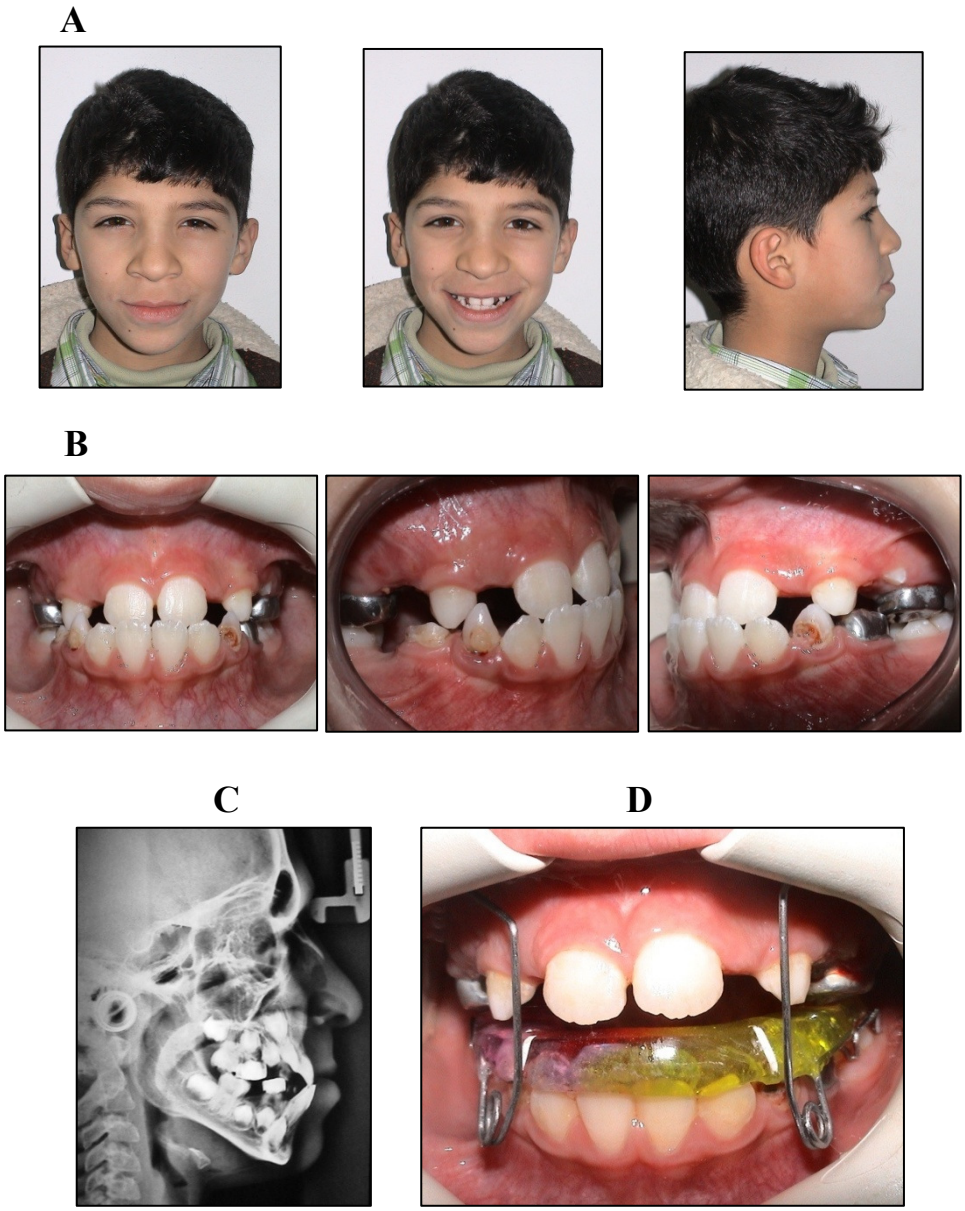

Fig. 8: Case 1: A, B and C; pre-operative extra-oral, intra-oral photographs and lat. Cephalogram at T1 respectively. D; TTSA inserted intra-orally.

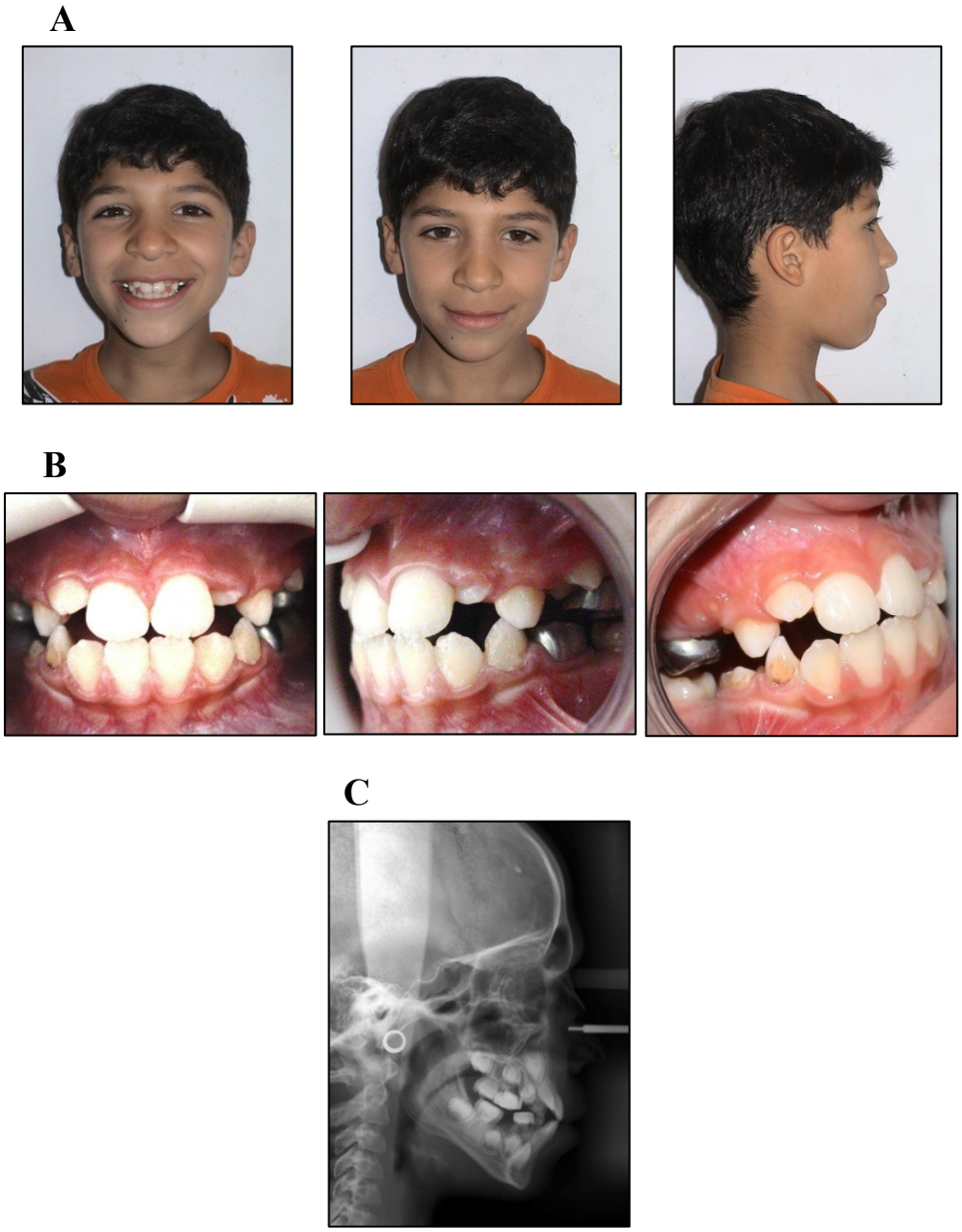

Fig 9: Case 1, A, B and C; Post-operative extra-oral, intra-oral photographs, and lat. cephalogram at T2 respectively.

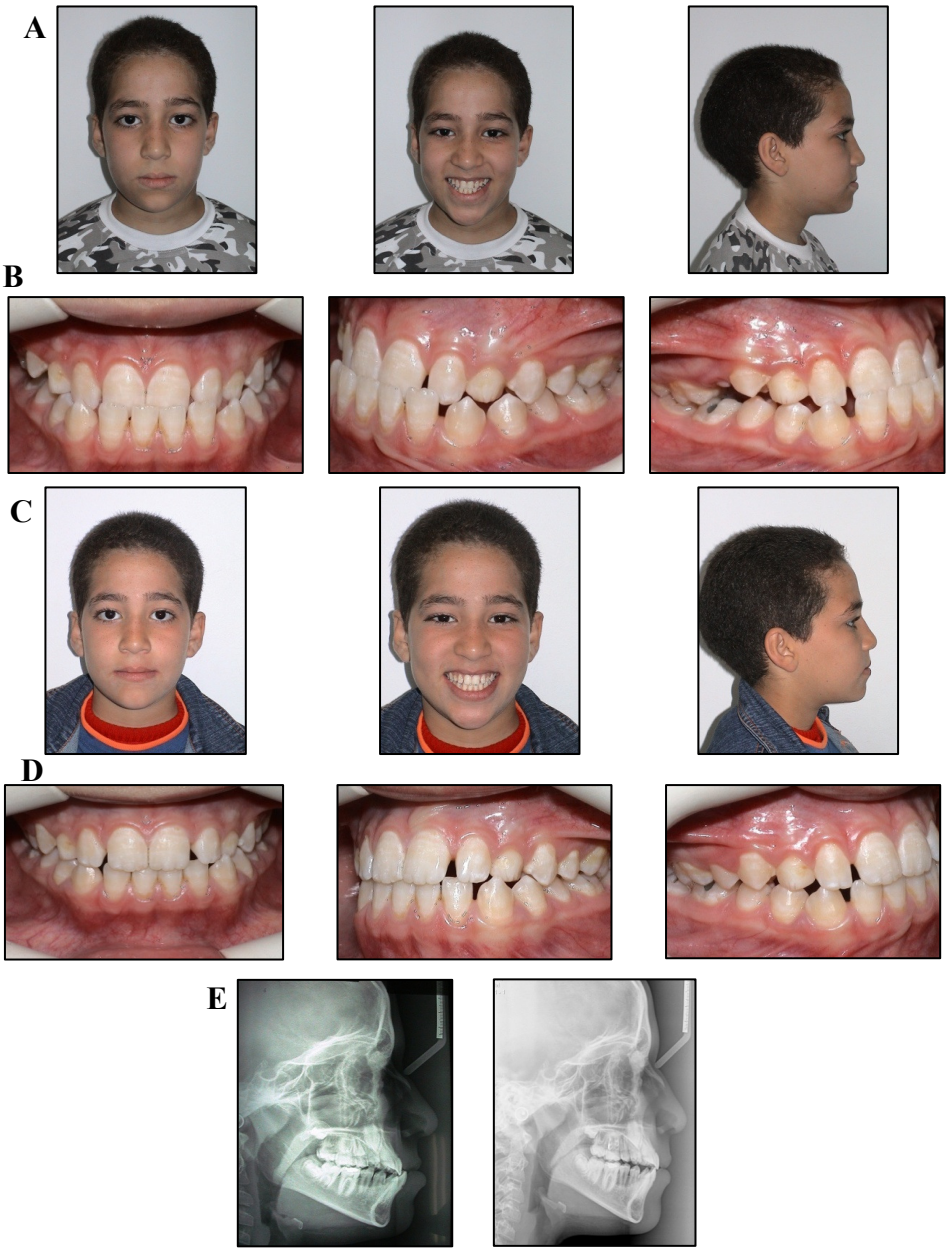

Fig 10: Case 2, A&B; pre-operative extra-oral and intra-oral photographs at T1, C&D; post-operative extra-oral and intra-oral photographs at T2 and E; lat. Cephalograms at T1 and T2 respectively.

REFERENCES

1. Guyer EC, Ellis EE III, McNamara JA Jr, et al. Components of class III malocclusion in juveniles and adolescents. Angle Orthod 1986;56:7.
2. Proffit WR. Contemporary Orthodontics. 4th ed. St Louis, Mo: Mosby; 2007:689–707.
3. Chong Y H, Ive JC, Artun J. Changes following the use of protraction headgear for early correction of Class III malocclusion. Angle Orthod. 1996;66:351–362.
4. Chen K, So LL. Sagittal skeletal and dental changes of reverse headgear treatment in Chinese boys with complete unilateral cleft lip and palate. Angle Orthod. 1996;66:363–372.
5. Tindlund RS. Orthopedic protraction of the midface in the deciduous dentition-Results covering 3 years out of treatment. J Craniomaxillofac Surg. 1989;17:17–19.
6. Tindlund RS, Rygh P, Boe OE. Orthopedic protraction of the upper jaw in cleft lip and palate patients during deciduous and mixed dentition periods in comparison with normal growth and development. Cleft Palate Craniofac J. 1993;30:182–194.
7. Tindlund RS, Rygh P. Maxillary protraction: different effects on facial morphology in unilateral and bilateral cleft lip and palate patients. Cleft Palate Craniofac J. 1993;30:208–221.
8. Buschang PH, Porter C, Genecov D, Sayler KE. Face mask therapy of preadolescents with unilateral cleft lip and palate. Angle Orthod. 1994;64:145–150.
9. GekKiow, Kaan SK. Dentofacialorthopaedic correction of maxillary retrusion with the protraction facemask - a literature review. Aust Orthod J. 1992;12:143–150.
10. Kokich VG, Shapiro PA, Oswald R, Koskinen-Moffett L, Clarren SK. Ankylosed teeth as abutments for maxillary protraction. A case report.Am J Orthod. 1985;88:303–307.
11. Guyman GW, Kokich VG, Oswald RJ. Ankylosed teeth as abutments for palatal expansion in the rhesus monkey.Am J Orthod. 1980;77:486–499.

12. Sheller B, Omnell L. Therapeutic ankylosis of primary teeth. J Clin Orthod. 1991;25:499–502.
13. Omnell ML, Sheller B. Maxillary protraction to intentionally ankylosed deciduous canines in a patient with cleft palate. Am J OrthodDentofacialOrthop. 1994;106:201–205.
14. Branemark PI. Osseointegration and its experimental background. J Prosthet Dent. 1983;50:399–410.
15. Adell R, Lekholm U, Rockler B, Branemark PI. A 15-year study of osseointegrated implants in the treatment of the edentulous jaw. Int J Oral Surg. 1981;10:387–416.
16. Block MS, Hoffman DR. A new device for absolute anchorage for orthodontics.Am J OrthodDentofacialOrthop. 1995;107: 251–258.
17. Roberts WE, Smith RK, Ziberman Y, Mozsary PG, Smith RS. Osseous adaptation to continuous loading of rigid endosseous implants. Am J Orthod. 1984;86:95–111.
18. Gray JB, Steen ME, King GJ, Clark AE. Studies on the efficacy of implants as orthodontic anchorage. Am J Orthod. 1983;83:311– 317.
19. Roberts WE, Marshall KJ, Mozsary PG. Rigid endosseous implant utilized as anchorage to protract molars and close an atrophic extraction site. Angle Orthod. 1990;60:135–152.
20. Higuchi KW, Slack JM. The use of titanium fixtures for intraoral anchorage to facilitate orthodontic tooth movement.Int J Oral Maxillofac Implants. 1991;6:338–344.
21. Roberts WE, Nelson CL, Goodacre CJ. Rigid implant anchorage to close a mandibular first molar extraction site. J Clin Orthod. 1994; 28:693–704.
22. Odman J, Lekholm U, Jemt T, Thilander B. Osseointegrated implants as orthodontic anchorage in the treatment of partially edentulous adult patients. Eur J Orthod. 1994;16:187–201.
23. Turley PK, Shapiro PA, Moffett BC. The loading of bioglasscoated aluminum oxide implants to produce sutural expansion of the maxillary complex in the pigtail monkey (Macacanemestrina). Archs Oral Biol. 1980;25:459–469.

24. Smalley WM, Shapiro PA, Hohl TH, Kokich VG, Branemark PI. Osseointegrated titanium implants for maxillofacial protraction in monkeys. Am J Orthod Dentofacial Orthop. 1988;94:285–295.
25. Parr AJ, Garetto LP, Wohlford ME, et al. Sutural expansion using rigidly integrated endosseousimplants:an experimental study in rabbits. Angle Orthod. 1997;67:283–290.
26. Singer SL, Henry PJ, Rosenberg I. Osseointegrated implants as an adjunct to facemask therapy: a case report. Angle Orthod 2000;70:253–62.
27. Enacar A, Giray B, Pehlivanoglu M, Iplikcioglu H. Facemask therapy with rigid anchorage in a patient with maxillary hypoplasia and severe oligodontia. Am J OrthodDentofacialOrthop 2003;123:571–7.
28. Hong H, Ngan P, Han G, Qi LG, Wei SH. Use of onplants as stable anchorage for facemask treatment: a case report. Angle Orthod 2005;75:453–60.
29. Kircelli BH, Pektas ZO. Midfacial protraction with skeletally anchored facemask therapy: a novel approach and preliminary results. Am J Orthod Dentofacial Orthop 2008;133:440–9.
30. Kircelli BH, Pektas ZO, Uckan S. Orthopedic protraction with skeletal anchorage in a patient with maxillary hypoplasia and hypodontia. Angle Orthod 2006;76:156–63.
31. Eid H. et al. Evaluation of a new intraoral appliance for treatment of Class III malocclusion. PhD Thesis, Faculty of Dentistry, Ain Shams University, Cairo, Egypt. 2007.
32. Hilgers J and Bennette R. The Pendulum Appliance part II. Clinical impression (Ormco). 1994; 3 (4) : 6-9 and 14-18.
33. Hilgers J. The Pendulum Appliance for class II Noncompliance Therapy. J ClinOrthod. 1992;XXVI (11): 706-714.
34. Proffit WR. Contemporary Orthodontics. 4th ed. St Louis, Mo: Mosby; 2007:372.
35. Cornelis MA, Scheffler NR, Mahy P, Siciliano S, De Clerck HJ, Tulloch JF. Modified miniplates for temporary skeletal anchorage in orthodontics: placement and removal surgeries. J Oral Maxillofac Surg 2008;66:1439–45.

36. Cornelis MA, Scheffler NR, Nyssen-Behets C, De Clerck HJ, Tulloch JF. Patients' and orthodontists' perceptions of miniplates used for temporary skeletal anchorage: a prospective study. Am J OrthodDentofacialOrthop 2008;133:18–24.
37. De Clerck H. et al. Dentofacial effects of bone-anchored maxillary protraction: A controlled study of consecutively treated Class III patients. . Am J Orthod Dentofacial Orthop 2010;138(5): 577–581.
38. T. Baccetti et al. Morphometric analysis of treatment effects of bone-anchored maxillary protraction in growing Class III patients. European Journal of Orthodontics 33 (2011) 121–125.
39. Gallagher RW. Miranda F: Maxillary protraction: treatment and post treatment effects, Am J Orthod Dentofacial Orthop 113:612-619, 1998.
40. McGill JS: Orthopedic alterations induced by rapid maxillary expansion and farce mask therapy. Ann Arbor, Mich, 1995.
41. Cozza P, Marino A: An orthopaedic approach to the treatment of Class III malocclusions in the early mixed dentition. Eur J Orthod. 2004 Apr; 26(2):191-9.
42. Bjork A: Prediction of mandibular growth rotation. Am J Orthod 55:585-599, 1969.
43. Skieller V Bjork A, Linde-Hansen T: Prediction of mandibular growth rotation evaluated from a longitudinal implant sample. Am J Orlhod 86:359-370, 1984.
44. Baccetti T, Franchi L, McNamara J AJr 1999 Thin-plate spline analysis of treatment effects of rapid maxillary expansion and facial mask therapy in early Class III malocclusion. European Journal of Orthodontics 21: 275–281.
45. Chang H P, Lin H C, Liu P H, Chang C H 2005 Geometric morphometric assessment of treatment effects of maxillary protraction combined with chin cup appliance on the maxillofacial complex. Journal of Oral Rehabilitation 32: 720–728.